

***Indirect Laryngoscopy
and Nasopharyngoscopy
Instructions***



WA[®]
Welch Allyn

Foreword

The purpose of this booklet is to acquaint the reader with the need and procedure for examining the Larynx and Nasopharynx areas.

It will reveal the true nature of hoarseness, and when regularly employed, the physician can confidently diagnose and advise treatment or consultation early in the course of a laryngeal disease. The early recognition of laryngeal abnormalities permits conservative therapy with maximum preservation of laryngeal tissue and the patient's voice.

Indirect nasopharyngoscopy can also be satisfactorily accomplished. It examines the back of the nose, including the eustachian tubes, for possible infections, blockages, tumors, and adenoid tissue in children.

We wish to express our sincere appreciation to Dr. Edwin W. Cocke, Jr., M.D., Clinical Professor, Department of Otolaryngology and Maxillofacial Surgery, University of Tennessee Center for the Health Sciences, Memphis, Tennessee, for his valuable assistance in the preparation of this instructional booklet.

The Larynx Illuminator

One of the factors that has discouraged many physicians from performing indirect laryngoscopy has been the unaccustomed use of the head mirror and the laryngeal mirror combined with the difficulty of positioning the patient and focusing the light source both on the mirrors and on the areas to be examined. This instrument eliminates many of the disadvantages of the head mirror system and may be employed with minimum difficulty.

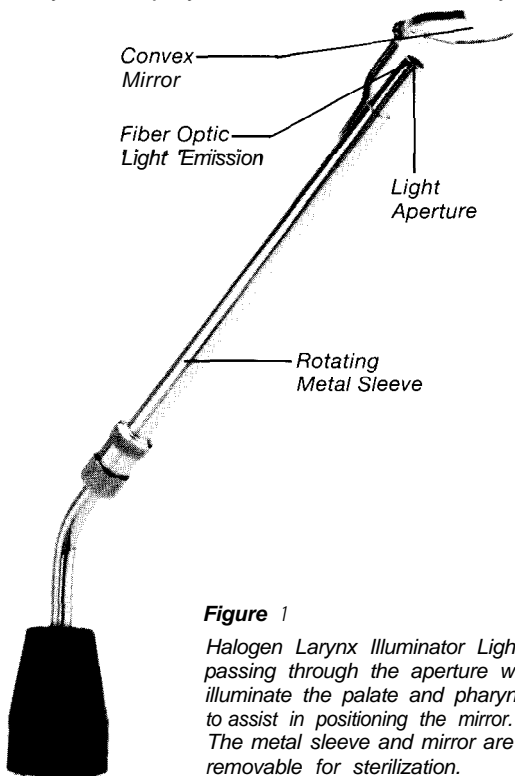


Figure 1

Halogen Larynx Illuminator Light passing through the aperture will illuminate the palate and pharynx to assist in positioning the mirror. The metal sleeve and mirror are removable for sterilization.

The Nasopharynx Illuminator

The nasopharyngeal mirror is identical to the laryngeal mirror except that it is round and smaller.

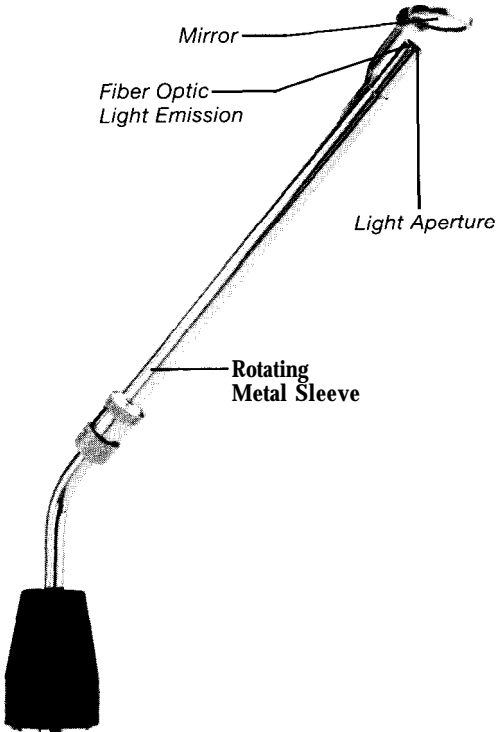


Figure 2
Halogen Nasopharynx

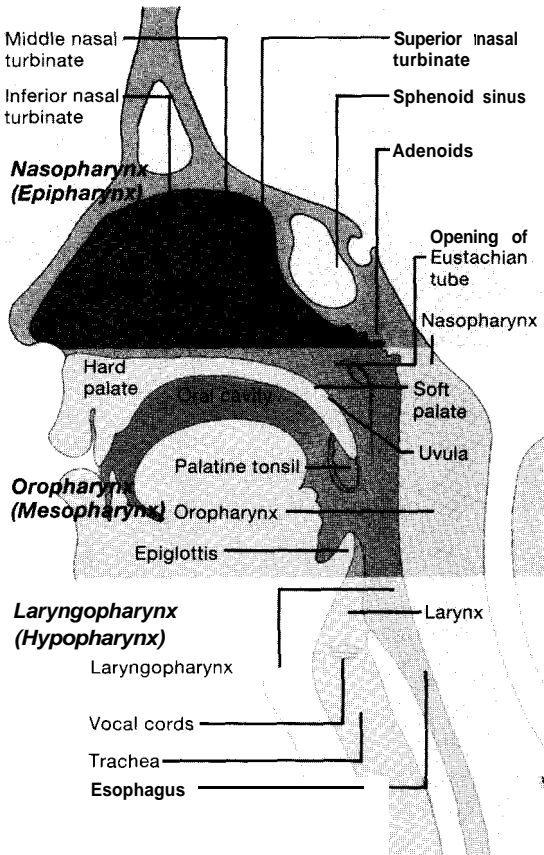


Figure 3

The pharynx has three divisions: the nasopharynx located between the base of the skull and the palate; the oropharynx between the palate and base of the tongue; and the laryngopharynx between the base of the tongue and the esophagus.

Examination by Indirect Laryngoscopy

To successfully examine the laryngopharynx with the illuminated Welch Allyn mirror, it is desirable for the light in the examining area to be subdued. The patient is reassured and asked to breathe through his mouth. Sedation may be required in apprehensive patients or topical anesthesia to the palate and pharynx in patients whose gag reflex is excessive. The physician must employ the instrument frequently enough to become proficient, to establish a routine, to gain confidence, and to become familiar with the normal anatomy of the laryngopharynx. The following steps will produce satisfactory results:

1. The examiner should sit to one side (patient's left) or in front of the patient to be examined.
2. The patient sits in a straight back chair with his hips firmly against the back rest, trunk forward, head back, chin extended, mouth open, and his tongue extended.
3. The Welch Allyn hand piece with attached laryngeal mirror is held in the examiner's right hand. The light switch is turned on to illuminate the fiber optic light source.
4. A gauze square wrapped about the patient's tongue facilitates holding it between thumb and middle finger of the left hand while the index finger elevates the upper lip. The patient may be requested to hold his own tongue while the examiner depresses it with a tongue blade held in his left hand.

5. The mirror is inserted into the mouth. Light passing through the light aperture facilitates positioning the mirror so it passes between the tonsils and elevates the soft palate. The patient is encouraged to breathe deeply through his mouth and relax. A topical anesthetic may be applied should there be excessive gagging.
6. The reflected light in the mirror now illuminates the base of the tongue and the laryngopharynx. A minor degree of rotation of the laryngeal mirror assists in illuminating and examining the various anatomical structures.
7. Variations in color, contour and motion of each side of the larynx when compared with identical structures of the opposite side should arouse suspicion that an abnormality exists.

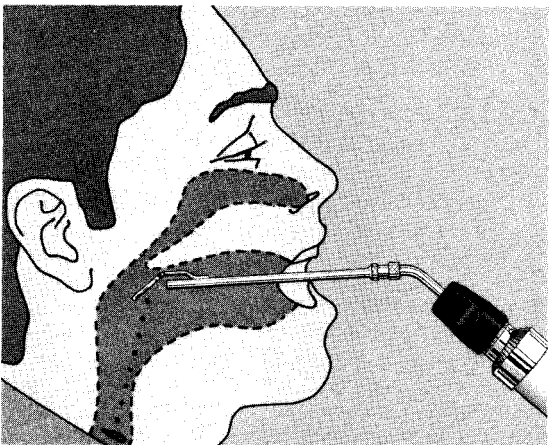


Figure 4

Reflected light in the mirror will illuminate the base of the tongue and laryngopharynx

8. The various anatomical structures composing the base of the tongue and laryngopharynx are examined in routine order: base of tongue, vallecula, epiglottis, each arytenoid cartilage, aryepiglottic folds, pyriform fossae and esophageal area.
9. The patient is asked to phonate the letter "a" and then the letter "e." The epiglottis moves forward so that its posterior surface may be examined followed by examination of the right and left false vocal cords, true vocal cords, anterior and posterior commissures. The mobility of each true cord is then evaluated.

Indirect Nasopharyngoscopy

Indirect nasopharyngoscopy (posterior rhinoscopy) is accomplished with the Nasopharynx Illuminator. Of interest is the "vault" of the nasopharynx and eustachian tubes, adenoid tissue, polyps and tumors.

The following steps will produce satisfactory examination results:

1. The examiner should sit to one side (patient's left) or in front of the patient to be examined.
2. The Welch Allyn hand piece with attached nasopharyngeal mirror is held in the examiner's right hand. The light switch is turned on to illuminate the fiber optic light source.
3. Following depression of the tongue with a tongue blade held in the left hand, the patient is asked to breathe simultaneously through his nose and mouth. This relaxes the soft palate.
4. The mirror is passed into the mouth along the surface of the tongue blade, coming to rest between the soft palate and the pharyngeal wall. Care should be taken to avoid touching the tongue, pharynx or palate with the mirror.
5. The handle of the mirror is depressed and rotated from side to side so that successive parts of the nasopharynx may be viewed.
6. Should excessive gagging ensue, topical anesthesia should be applied.

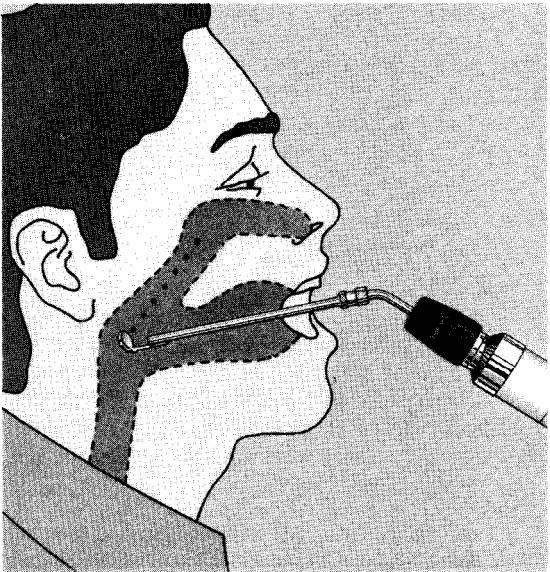


Figure 5

Reflected light in the mirror will illuminate the posterior nose and nasopharynx.

7. Should the space between the palate and pharyngeal wall be too narrow for examination, a soft palate retractor may be required.
8. Variations in color and contour of each side of the nasopharynx when compared with identical structures of the opposite side should arouse suspicion that an abnormality exists.
9. The various anatomical structures that may be viewed include the eustachian tube orifice, torus tubarius, fossa of Rosenmuller, adenoid, middle turbinate, inferior turbinate and nasal septum.

Conclusion

The instructions given in this manual are presented as a guide to successful laryngeal and nasopharyngeal examinations. These examinations should always be included in a complete physical examination. In addition to revealing the true nature of hoarseness, the physician can confidently diagnose and advise treatment or consultation in the earliest stages of disease. Early recognition of abnormalities permits conservative therapy with maximum preservation of tissue. When used regularly and correctly, the Larynx Illuminator and Nasopharynx Illuminator can serve as one of the physician's most effective pieces of diagnostic equipment.



Welch Allyn, Inc.
4341 State Street Road
P.O. Box 220
Skaneateles Falls, NY
13153-0220

Form No. 270092-3